

Takotsubo (Stress) Cardiomyopathy

Scott W. Sharkey, MD; John R. Lesser, MD; Barry J. Maron, MD

Whenever a new and previously unrecognized medical condition enters our consciousness, considerable confusion and uncertainty can ensue. If a patient is afflicted by such a disease state, the natural reaction is, "I have never heard of what I have," triggering considerable personal and family anxiety. Such is the case with the condition we now call takotsubo cardiomyopathy, which has received considerable attention from the media and has been assigned a myriad of names in the literature.

Historical Background and Increasing Visibility

Initial recognition of takotsubo cardiomyopathy occurred in Japan in 1990, with the first report emerging from the United States in 1998. Thereafter, scientific interest in this condition has increased steadily and dramatically. For example, in 2000, only 2 publications were recorded, compared with nearly 300 in 2010 (Figure 1). Now, takotsubo is widely recognized, with reports from 6 continents and diverse countries, including France, Belgium, Mexico, Australia, Spain, South Korea, China, Brazil, Germany, Israel, South Africa, Turkey, and Iceland.

What Is Takotsubo?

The Acute Illness

Takotsubo cardiomyopathy starts abruptly and unpredictably, with symptoms of chest pain and, often, shortness of breath, usually triggered by an emotionally or physically stressful event, and with a predilection for women older than 50 years of age (only 10% in men). Most patients go to the emergency department because of concern they are experiencing a heart attack, a much more common acute heart condition caused by a blocked coronary artery (the Table). Although patients with takotsubo do not have significantly narrowed coronary arteries, in the early hours takotsubo and heart attacks share many similarities in presentation, including chest pain and breathlessness, as well as abnormalities in both the electrocardiogram and blood biochemical tests. Even experienced physicians can be challenged to distinguish between the two, at least until an x-ray study of the coronary arteries and left ventricle with dye establishes the absence of severe plaque buildup in a coronary artery as well as the unusual shape of the left ventricle (ie, pumping chamber)

Table. Common Questions Asked About Tako-Tsubo

<ul style="list-style-type: none"> Did I have a "heart attack"? 	<p>No. Strictly speaking, the term "heart attack" indicates heart muscle injury due to a blocked coronary artery. The heart muscle injury in tako-tsubo cardiomyopathy is not caused by a blocked artery.</p>
<ul style="list-style-type: none"> Who is at risk? 	<p>For reasons unknown, women above age 50 y are much more susceptible to the tako-tsubo cardiomyopathy. Traditional risk factors for heart disease (smoking, diabetes, high blood pressure, high cholesterol) do not apply to tako-tsubo.</p>
<ul style="list-style-type: none"> Will this happen to me again after future stressful events? 	<p>Probably not. Fully 95% of patients do not have a recurrence and endure a variety of stressful events without harm to the heart.</p>
<ul style="list-style-type: none"> Is there something "wrong" with my ability to deal with stress? 	<p>Current evidence suggests that tako-tsubo cardiomyopathy is a reflex response controlled by the autonomic nervous system.</p>
<ul style="list-style-type: none"> Can this affect my family members? 	<p>There is no current evidence to suggest a familial inheritance of tako-tsubo cardiomyopathy.</p>
<ul style="list-style-type: none"> Will my heart be strong in the future? 	<p>Long-term follow-up of patients suggests no deterioration of heart muscle strength after a tako-tsubo event.</p>

From the Minneapolis Heart Institute Foundation at Abbott Northwestern Hospital, Minneapolis, MN.

The information contained in this *Circulation* Cardiology Patient Page is not a substitute for medical advice, and the American Heart Association recommends consultation with your doctor or healthcare professional.

Correspondence to Scott W. Sharkey, MD, Minneapolis Heart Institute Foundation, 920 E 28th St, Ste 300, Minneapolis, MN 55407. E-mail scott.sharkey@allina.com

(*Circulation*. 2011;124:e460-e462.)

© 2011 American Heart Association, Inc.

Circulation is available at <http://circ.ahajournals.org>

DOI: 10.1161/CIRCULATIONAHA.111.052662

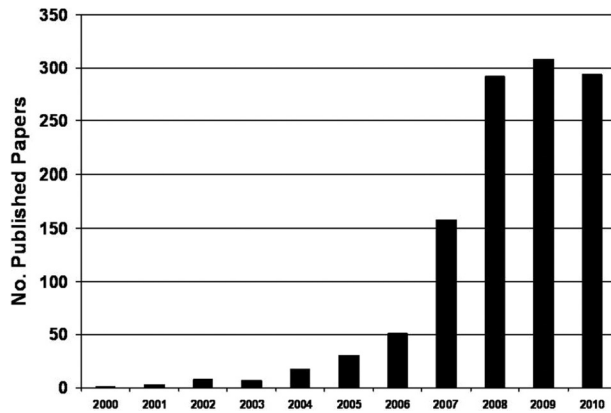


Figure 1. Increasing number of takotsubo cardiomyopathy publications by year, 2000 to 2010.

that has given takotsubo its unique name (Figure 2).

This distinctive shape includes a narrow upper portion (neck) in contrast with the lower enlarged portion that contracts poorly and closely resembles the ceramic Japanese takotsubo pot used to collect an octopus. Because a large proportion of the heart muscle is injured, heart failure can occur (ie, low blood pressure and fluid buildup in the lungs).

Hospital Stay and Recuperation

An echocardiogram (ultrasound) and sometimes a magnetic resonance imaging study are performed to evaluate the heart's pumping ability. Patients are in the intensive care unit for at least 24 hours, during which time vital signs are monitored and blood is tested for troponin (a protein released by injured heart muscle). Commonly used medications include β -blockers and angiotensin-converting enzyme inhibitor drugs, both of which promote recovery of heart muscle. Drugs that interfere with blood clotting (anticoagulants) may be administered briefly to avoid a stroke caused by a blood clot traveling from the heart to the brain.

Major life-threatening complications are infrequent. Low blood pressure (hypotension) requires administration of intravenous drugs or, in extreme cases, a temporary internal blood pressure support device (intra-aortic balloon pump). Fluid buildup in the lungs (congestive heart failure) ne-

cessitates drugs to promote urine production (diuretics) or occasionally the temporary use of a breathing support device (mechanical ventilator). A chaotic heart rhythm may require rhythm-stabilizing drugs or rarely electric shock (cardioversion).

Fortunately, with timely recognition and supportive therapy, takotsubo events are reversible, and recovery is usually rapid and complete. Heart function (contraction) gradually improves over several days and is usually normal by hospital discharge (3–7 days). The term stunned heart muscle is commonly used to indicate that injury in takotsubo, although initially profound, is only temporary. Drugs are discontinued once heart contraction has returned to normal.

Importance of Stress

In 85% of cases, takotsubo is triggered by an emotionally or physically stress-

ful event that precedes the onset of symptoms by minutes to hours. Emotional stressors include grief (death of a loved one), fear (armed robbery, public speaking), anger (argument with spouse), relationship conflicts (dissolution of marriage), and financial problems (gambling loss, job loss). Physical stressors include acute asthma, surgery, chemotherapy, and stroke.

Identifying the stress trigger is occasionally challenging, and in 15% of cases cannot be elicited by careful history. Whether chronic stress can trigger this condition is unknown. Because stress is such an important part of takotsubo, the terms stress cardiomyopathy and broken heart syndrome have been used frequently.

What Causes Takotsubo?

Although the basic cause of this condition is unresolved, the frequent association with stress has focused attention on the autonomic nervous system. It has been suggested that when powerful hormones such as adrenaline are released in excess, the heart muscle can be damaged in patients with takotsubo. In fact, events have been reported in patients after accidental overdose of adrenaline or associated with adrenaline-producing tumors (pheochromocytoma).

What Is the Long-Term Outlook?

With proper recognition and management, nearly all patients survive

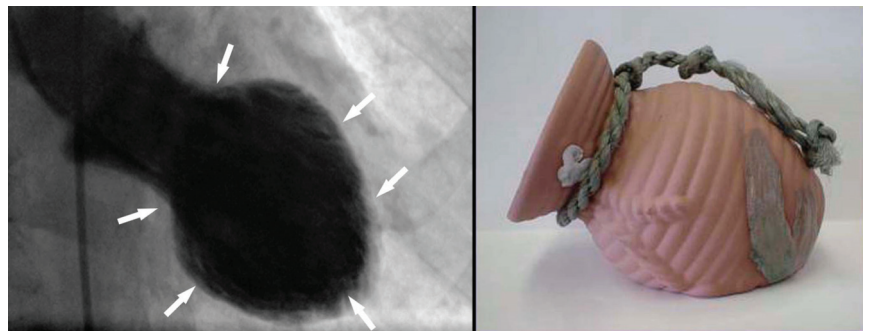


Figure 2. Left, X-ray of the heart during the contraction phase from a patient with takotsubo. Note the distinctive shape with a narrow neck and ballooned lower portion (arrows), which contracts abnormally. Right, The Japanese takotsubo (ceramic pot used to trap octopus) has a shape that closely resembles that of the heart on the left. This image courtesy Dr Satoshi Kurisu, Hiroshima, Japan.

an acute takotsubo episode. However, in approximately 5% of patients, a second (or third) stress-induced event may occur. Patients who suffer 1 episode of stress-induced cardiomyopathy should be confident that the chance of another episode is very low, even in the face of future unanticipated stressful circumstances. Although there is no evidence that drugs used in this syndrome prevent recurrences, multiple episodes do not produce cumulative damage. It is not understood why a specific stressful event will, on one occasion, trigger this condition, whereas at another time, a similar circumstance (even more stressful) does not.

Sources of Funding

This work was supported in part by a grant from The Hearst Foundations, New York, NY.

Disclosures

None.

Additional Resources

Sharkey SW, Windenburg DC, Lesser JR, Maron MS, Hauser RG, Lesser JN, Haas TS, Hodges JS, Maron BJ. Natural history and expansive clinical profile of stress (tako-tsubo) cardiomyopathy. *J Am Coll Cardiol*. 2010;55:333–341.

Sharkey SW, Lesser JR, Zenovich AG, Maron MS, Lindberg J, Longe TF, Maron BJ. Acute and reversible

cardiomyopathy provoked by stress in women from the United States. *Circulation*. 2005;111:472–479.

Wittstein IS, Thiemann DR, Lima JA, Baughman KL, Schulman SP, Gerstenblith G, Wu KC, Rade JJ, Bivalacqua TJ, Champion HC. Neurohumoral features of myocardial stunning due to sudden emotional stress. *N Engl J Med*. 2005;352:539–548.

Bybee KA, Prasad A. Stress-related cardiomyopathy syndromes. *Circulation*. 2008;118:397–409.

Sharkey SW, Lesser JR, Maron MS, Maron BJ. Why not just call it Tako-tsubo cardiomyopathy? A discussion of nomenclature. *J Am Coll Cardiol*. 2011;57:496–500.

Takotsubo (Stress) Cardiomyopathy
Scott W. Sharkey, John R. Lesser and Barry J. Maron

Circulation. 2011;124:e460-e462

doi: 10.1161/CIRCULATIONAHA.111.052662

Circulation is published by the American Heart Association, 7272 Greenville Avenue, Dallas, TX 75231

Copyright © 2011 American Heart Association, Inc. All rights reserved.

Print ISSN: 0009-7322. Online ISSN: 1524-4539

The online version of this article, along with updated information and services, is located on the
World Wide Web at:

<http://circ.ahajournals.org/content/124/18/e460>

Permissions: Requests for permissions to reproduce figures, tables, or portions of articles originally published in *Circulation* can be obtained via RightsLink, a service of the Copyright Clearance Center, not the Editorial Office. Once the online version of the published article for which permission is being requested is located, click Request Permissions in the middle column of the Web page under Services. Further information about this process is available in the [Permissions and Rights Question and Answer](#) document.

Reprints: Information about reprints can be found online at:
<http://www.lww.com/reprints>

Subscriptions: Information about subscribing to *Circulation* is online at:
<http://circ.ahajournals.org/subscriptions/>